

WMJ (Wormadewa Medical Journal), Vol. 6 No. 2 November 2021, Hal. 67-74

Case Report: Successful Management of Critical Pulmonary Stenosis in a 12-Month-Old Boy

Dyahris Kuntartiwi¹, Erviani Maulidia², Renny Suwarniaty³

^{1,2,3}Departemen Ilmu Kesehatan Anak, RSUD Dr Saiful Anwar, Fakultas Kedokteran Universitas Brawijaya, Malang

Email¹: dyahris08.fk@ub.ac.id

Abstract

Critical pulmonary stenosis (PS) is used in infants born with very severe narrowing valves and requires treatment soon after birth. At four months old, an A-12-month-old boy was diagnosed with critical pulmonary stenosis but still successfully managed by percutaneous transluminal balloon valvuloplasty (PTBV) with satisfactory results without serious complications. Since he was born, cyanosis was seen at his lips and fingertip, with oxygen saturation around 60% until 70%. Echocardiography showed critical pulmonary stenosis, atrial septal defect (ASD), and patent ductus arteriosus (PDA). Percutaneous transluminal balloon valvuloplasty (PTBV) is accepted as the treatment of choice for critical pulmonary valve stenosis in many centers worldwide with significant results. After PTBV, he experienced improvement condition as no cyanosis was observed and oxygen saturation was 96%. This case was our first PTBV intervention case in our hospital and gave satisfactory results, although the intervention was delayed due to our limited resources before.

Keywords: cyanosis, critical pulmonary stenosis, percutaneous transluminal balloon valvuloplasty

Abstrak

[Laporan kasus : Tatalaksana stenosis pulmonal kritis pada anak usia 12 bulan dengan Valvuloplasti Balon Transkateter Perkutan]

Stenosis pulmonal kritis merupakan istilah yang biasanya dipakai mendefinisikan adanya penyempitan kritis katup pulmonal /katup pembuluh nadi paru pada bayi baru lahir dan membutuhkan tindakan intervensi segera setelah lahir. Pada laporan kasus ini seorang anak laki-laki usia 12 bulan yang sudah terdiagnosis sebagai stenosis pulmonal kritis sejak dilahirkan dengan adanya klinis sianosis pada ujung jari kaki dan tangan serta mukosa bibir biru dengan saturasi oksigen 60%-70% yang menjalani intervensi kardiologi valvuloplasti balon transkateter perkutan dengan hasil yang memuaskan tanpa adanya komplikasi serius. Pada pemeriksaan ekokardiografi awal didapatkan hasil stenosis pulmonal kritis, defek septum atrium (DSA) dan ductus arteriosus paten (DAP). Valvuloplasti balon transkateter perkutan merupakan terapi utama pilihan untuk stenosis pulmonal kritis pada semua senter kardiologi di dunia dengan hasil yang sangat memuaskan. Setelah tindakan klinis tidak didapatkan sianosis dan saturasi oksigen meningkat hingga 96%. Kasus ini sangat jarang dan merupakan kasus intervensi valvuloplasti balon transkateter perkutan yang pertama di rumah sakit ini dengan hasil yang sangat memuaskan meskipun tindakan dilaksanakan agak terlambat karena keterbatasan sumber daya pada waktu sebelumnya.

Kata Kunci: sianosis, stenosis pulmonal kritis, percutaneous transluminal balloon valvuloplasty

INTRODUCTION

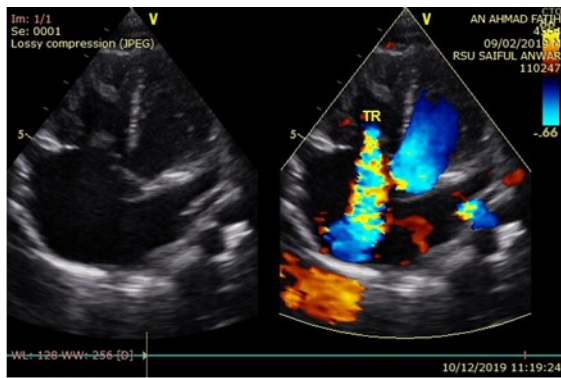
Critical pulmonary stenosis (PS) is used in infants born with very severe narrowing valves and requires treatment soon after birth. The prevalence of critical pulmonary stenosis has been reported at 0.6 to 0.8 cases per 1000 live births in the United States. The report about the prevalence of critical PS in Indonesia is still unknown. In our case, only

one patient in one year was diagnosed with critical pulmonary stenosis at RSUD Dr. Saiful Anwar General Hospital in Malang. We successfully managed critical pulmonary stenosis in a 12-month old boy by percutaneous transluminal balloon valvuloplasty (PTBV). Treatment by PTBV is a choice of procedure for all ages.¹

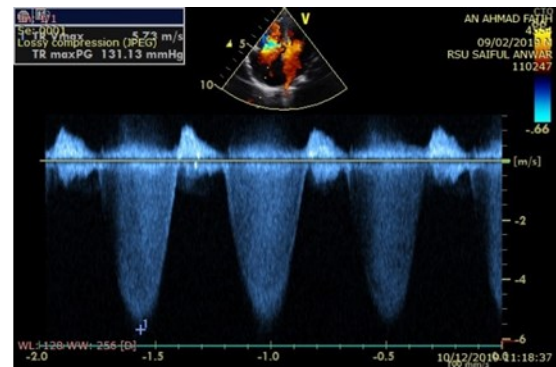
CASE REPORT

A 12-month-old boy observed cyanosis and was seen at his lips and fingertip since he was born. He had difficulty breathing while he was breastfed. Since he was four months old, there was no weight gain, and her mother brought him to a pediatric metabolic and nutrition consultant at RSUD Dr. Saiful Anwar hospital to solve a nutritional problem. In July 2019, when he was five months old, a Pediatric cardiologist referred him to RSUD Dr. Soetomo hospital in Surabaya for cardiology intervention due to lack of resources in our hospital. Since then, the patient has regularly visited the pediatric cardiology outpatient clinic (OPC) in RSUD Dr.

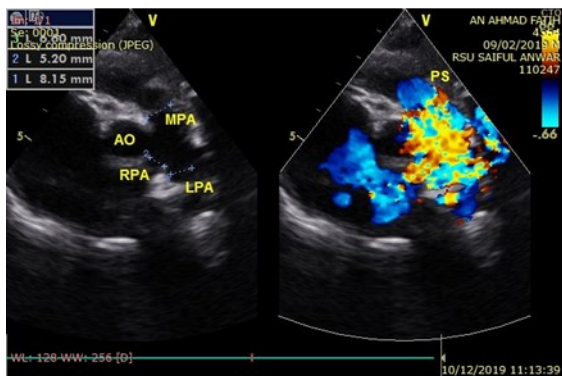
Soetomo hospital. When he reached one year old, there was no cardiology intervention done for his critical PS, and the patient became more cyanotic than before. After consultation at pediatric cardiology OPC in our hospital again, we decided to perform elective cardiology intervention PTBV. There was a delay in the development progress, and anthropometric measurement revealed body weight was 7.3 kilograms, height was 69 centimeters, head circumference was 45 centimeters, and upper arm circumference was 12 centimeters. These conditions indicated moderate malnutrition for children aged 12 months old because it showed the growth of children aged 8-months-old.



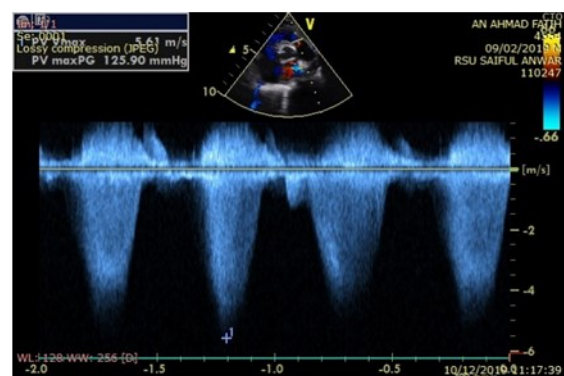
1



2



3



4

Figure 1. 1. Severe tricuspid regurgitation 2. Pressure gradient of tricuspid regurgitation 143 mmHg
3. Critical pulmonic stenosis 4. Pressure gradient of pulmonary valve 125.9 mmHg

The vital sign showed heart rate was 125 times per minute, respiratory rate was 48 times per minute, saturation 60%-70%, and the temperature was 37 C. Head examination revealed cyanotic at his lips and tongue mucosa. Chest examination showed the symmetric movement of chest walls and minimal subcostal retraction. There was a vesicular breath sound in both lungs, and there were no rales and wheezing. From auscultation, we heard a systolic ejection murmur at the upper left sternal border, grade 3/6. There was no abnormality at the abdomen, anorectal or urogenital. There was cyanotic at his fingertip, with warm

acral and capillary refill time less than 2 seconds.

Chest X-Ray showed cardiomegaly, apex upward as right ventricular hypertrophy, and decreased pulmonary vascular marking. Echocardiography demonstrated severe tricuspid regurgitation (PG 142.93 mmHg), mild mitral regurgitation, mild pulmonary regurgitation, and pulmonary stenosis severe valvular type (PG 83 mmHg) which from these results, can be concluded critical pulmonary stenosis, atrial septal defect, and patent ductus arteriosus.

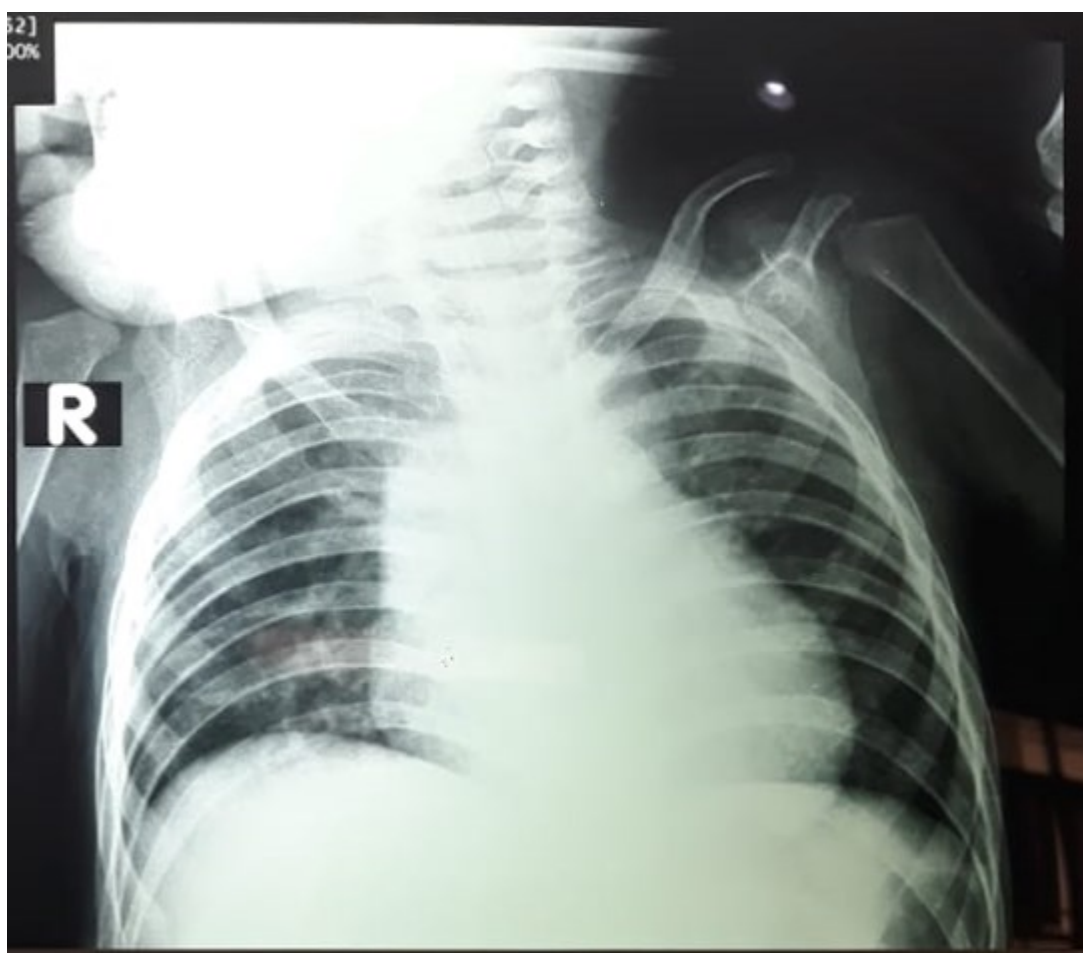


Figure 2. Chest X-Ray showed pneumonia and there was cardiomegaly and decreased pulmonary vascular marking.

Before PTBV was done, we must evaluate other laboratory examinations for intervention preparation. There was normal hemostatic function and no evidence of Human Immunodeficiency Virus (HIV), Hepatitis B, and Hepatitis C infection. We consulted with the anesthesia and reanimation department for general anesthesia and consulted with a pediatric intensivist for PICU and treatment after the PTBV procedure.

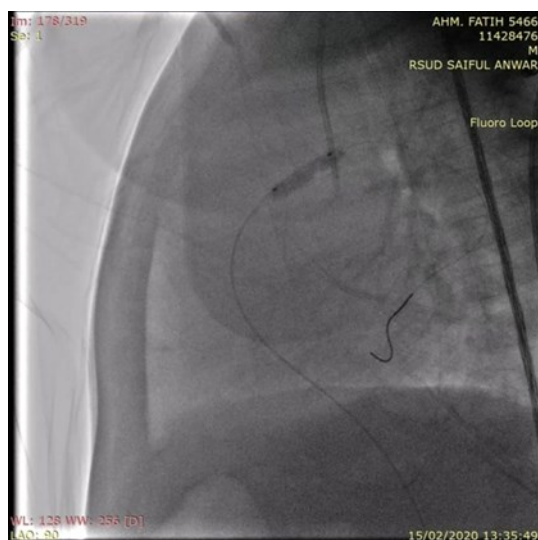We transferred the patient to the cath lab for the PTBV procedure, and the patient was already fasting for 6 hours; we gave intravenous fluid and antibiotic prophylaxis.

After the disinfection procedure, the left femoral vein was cannulated with sheath 5F; we inserted the MPA 1 5F catheter under guiding Terumo wire length around 150 cm to inferior vena cava, then to the right atrium and then to the right ventricle. Lateral angiography with contrast injection was performed to see pulmonary valve annulus. The MPA 1 5F catheter could not enter the pulmonary artery valve, so we first dilated the pulmonary valve using a coronary sapphire ballon NC 4.0 under guiding wire run-through floppy and deflated with deflator 12 ATM. After dilatation, we inserted MPA 1 5F catheter guiding coronary wire to MPA. We pulled out

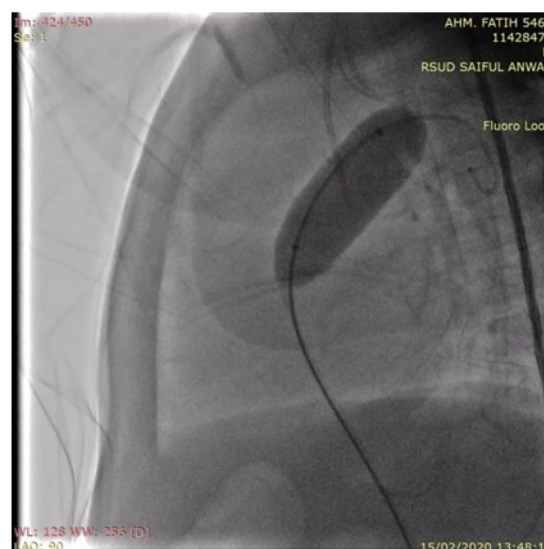
the coronary wire and replaced it with an Amplatzer Thysak balloon guiding Amplatzer stiff wire. Inflate the balloon in the pulmonary valve until we see the balloon's waist, and repeat the procedure twice. We pulled out the Thysak balloon and kept the wire Amplatzer extra stiff wire. We introduced MPA 1 5F catheter under the guiding Amplatzer extra stiff wire. We measured pressure from pulmonary arteries to the right ventricle.

Before the PTBV procedure, the pressure from the pulmonary artery to the right ventricle was 129/23/4 mmHg to 70/37/49 mmHg. After the PTBV procedure, pullback pressure from the pulmonary artery to the right ventricle was 58/25/39 mmHg to 46/32/38 mmHg. Saturation before a procedure is 60-70%. Saturation evaluation after the PTBV increases to 96% with heart rate 115 times/minute.

The patient was transferred to PICU after the PTBV procedure due to lung overflow, and we gave furosemide intravenously intermittently for 24 hours also for observation. The patient was transferred again to the ward after 24 hours of observation, and we did an echocardiography evaluation with the result of pressure gradient at pulmonary valve was 22 mmHg. It means there was no residual pulmonary stenosis.



1



2

Figure 3. During PTBV 1. Dilate pulmonary valve using a coronary sapphire ballon
2. Inflate the Thysak balloon in the pulmonary valve

Now his mother regularly brings him to visit Pediatric cardiology OPC, and at the age of 1 year, six months old, his body weight is 7.3 kilograms, and he reaches improvement at developmental status. We still monitor this patient's growth and development status because he still suffers from undernourishment, short stature, and developmental delay.

DISCUSSION

Critical PS is used in infants born with very severe narrowing valves (greater than 90 mmHg). From echocardiography revealed that the pressure gradient of a pulmonary valve on this patient was 125.90 mmHg. In this case, only one patient in 1 year was diagnosed with critical pulmonary stenosis at Saiful Anwar General Hospital Malang. Clinical presentation of infants with critical pulmonary valve stenosis is similar to that of infants with pulmonary atresia¹. On physical examination, the infant is cyanotic with similar oxygen saturations in all extremities. Mild tachypnea is present, but respiratory distress is absent. The peripheral pulse and perfusion are normal. The large volume of blood passing into the right ventricle causes a normal to increased right ventricular impulse.

The first heart sound is normal or may be obscured by the tricuspid regurgitation murmur. No extra heart sounds are present. The second heart sounds single. A systolic ejection murmur heard best at the left lower sternal border and radiating toward the right anterior chest is caused by tricuspid valve regurgitation. The chest radiograph usually shows an enlarged right atrium, and the central blood vessels are of normal size. The electrocardiogram showed right axis deviation. The echocardiography showed severe tricuspid regurgitation with an enlarged right atrium is often present. Forward flow may be limited that it cannot be distinguished from the turbulence in the main pulmonary artery caused by ductal flow striking the atretic valve. Thus, definitive valve patency is often a small jet of pulmonary regurgitation visualized by color Doppler in the right ventricular outflow tract.

In this patient, we observed cyanosis on his fingertips and lips also tongue mucosa. The oxygen saturation is around 60% until 70%. At birth, the baby didn't cry spontaneously, tachypnea, cyanosis on the lips, and nails. Following the clinical presentation of infants with critical pulmonary valve, stenosis is similar to that of infants with pulmonary atresia. On physical examination, the infant is cyanotic with similar oxygen saturations in all extremities. Mild tachypnea is present, but respiratory distress is absent. The peripheral pulse and perfusion are normal.

We found cyanotic on lips and nails on physical examination, and from thorax examination, we can hear systolic ejection murmur on mid clavicle line Sinistra ICS II-III grade 3/6. The large volume of blood passing into the right ventricle causes a normal to increased right ventricular impulse. The first heart sound is normal or may be obscured by the tricuspid regurgitation murmur. No extra heart sounds are present. The second heart sounds single. A systolic ejection murmur heard best at the left lower sternal border and radiating toward the right anterior chest is caused by tricuspid valve regurgitation. Chest X-Ray showed pneumonia, and there was cardiomegaly and decreased pulmonary vascular marking. From an electrocardiogram, right axis deviation (RAD) may be seen in critical pulmonary stenosis. The chest radiograph usually shows an enlarged right atrium, and the central blood vessels are of normal size. The electrocardiogram showed right axis deviation.

It is important to recognize that a newborn with critical congenital heart disease may show little evidence of cardiovascular compromise on physical examination in the first 24 to 48 hours of life. In this case, the patient has been early diagnosed, so he has been given the management of heart failure. Malnutrition is highly prevalent among CHD infants and plays an important role in mortality, hospital infections, and increased length of stay (LOS) of such infants. Regarding the limited protein and fat reserves, high energy expenditure, and increased energy requirement for fur-

ther growth, infants are more prone to malnutrition than adults. Newborn infants with CHD, particularly those with stenosis pulmonary, will commonly have poor postnatal weight gain despite the good birth weight. The patient was breastfed since he was born now. The quantity and frequency of formula milk feeding is 80 cc per 4 hours and added with red rice porridge via enteral per NGT. The heart failure condition was Ross class 1, which indicates mild heart failure. At present, the patient receives an additional 3x4 tablespoon filter porridge by mouth. Weight gain was difficult to rise when he was seven months old. According to the growth chart, in this patient, we were diagnosed with undernourishment. He experienced difficulty reaching postnatal weight gain.

Although infants with severe pulmonary valve stenosis may be stable, those with critical obstruction of the pulmonary valve require administration of prostaglandin E1 to maintain adequate pulmonary blood flow through the ductus arteriosus. Prostaglandin E1 has been lifesaving for newborns with critical congenital heart disease.⁶ In our patient, we didn't give Prostaglandin E1 at birth because of the drugs available at our hospital, so we decided to refer the patient to RSUD Dr. Soetomo General Hospital for cardiology intervention PTBV and monitor clinical manifestation with a saturation target of more than 70%.

ercutaneous balloon valvuloplasty is the initial procedure for neonates with critical or severe pulmonary stenosis. Balloon valvuloplasty procedures for critical or severe pulmonary stenosis in the neonate are performed in the cardiac catheterization laboratory, usually with the patient intubated and sedated or under general anesthesia. We performed lateral RV angiography to visualize pulmonary valve annulus more correctly and advanced coronary wire also coronary balloon first before advancing Thysak balloon to open the pulmonary valve.

The probability of an initial successful balloon valvuloplasty has improved over the years and tends to be better in

large-volume centers. Several significant series reported, or including fewer than 20 patients, showed failure rates of 20%~45%. From large centers, the rate of failure to cross the pulmonary valve and achieve an initial balloon valvuloplasty is closer to 5%-10%. This condition shows that the patient has experienced improvement after percutaneous transcatheter balloon valvuloplasty. The oxygen saturation among 90-96% and didn't show cyanosis in this patient. The weight is also increased by 700 grams in 6 months. In accordance with most patients with critical stenosis will continue to have at least mild desaturation when the ductus completely closes due to continued right-to-left atrial level shunting. Time is required for the restoration of several variables to near-normal conditions.

Percutaneous transluminal balloon valvuloplasty for critical PS is a significantly safe procedure. Postoperative immediate complications are remarkably minimal. Some early postoperative complications are thrombosis, hemorrhage from the puncture site, systemic hypotension, and transient bradycardia. However, few of these complications can be inevitable. Meticulous pre-operative preparations and per-operative scrupulous concentration to the procedure may preclude or downgrade the complications. Potential disadvantages of this treatment are pulmonary valve restenosis, rupture of the pulmonary artery walls, and post-interventional high-grade valve insufficiency. The patient suffered from undernourishment, developmental delay, and short stature. It is a consequence of critical pulmonary stenosis with delayed treatment. However, the patient regularly visits OPC of pediatric cardiology, pediatric metabolic and nutrition, also pediatric growth and development.

CONCLUSION

A 12-month-old boy was diagnosed with Critical Pulmonary Stenosis. The patient got delayed treatment for Critical PS. PTBV was done on February 12th, 2020, with satisfactory results. This is the first case of PTBV in our hospital. The oxygen saturation among 90-96% and didn't show

cyanosis in this patient—the weight increased by 1100 grams in 6 months.

ACKNOWLEDGEMENT

We would like to thank you to the RSUD, Dr. Saiful Anwar Malang which allowed us to treat this case and present this case as our experience clinical case there.

REFERENCES

1. Park MK. Pediatric cardiology for practitioners. Seventh edition. United States of America: Philadelphia: Elsevier; 2021. p. 150-2.
2. Soeroso S, Sastrosoebroto H. Penyakit jantung bawaan non sianotik. In: Sastroasmoro S, Mulyadi M Djer, Editors. Buku ajar kardiologi anak, Jakarta: Badan Penerbit Ikatan Dokter Anak Indonesia; 2020. p. 245-50.
3. Khalil Anita. Essential pediatric Cardiology. Second edition. India: New Delhi: Jaypee Brother Medical Publisher(P) Ltd; 2011:145-9.
4. Cheatham JP. Pulmonary stenosis. In Garson A, Bridker JT, McNamr DG (Eds): The Science and Practice of Pediatric Cardiology, Vol I, Philadelphia PA: Lea & Febiger: 2012; 1207-1256.
5. Sommer RJ, Rhodes JF, Pamess IA. Physiology of critical pulmonary valve obstruction in the neonate. Cathet Cardiovasc Interven 2000; 50:473479.
6. O’Laughlin MP, Ringel RD. Diagnostic and therapeutic cardiac catheterization. In: Nichols DC, Ungerleider RM, Spevak PJ, Greeley WJ, Cameron DE, Lappe DG, et al. Critical heart disease in infant and children. United States of America: Philadelphia: Elsevier; 2006. p 464.
7. Seri Istvan, Kluckow Martin. *Hemodynamics and Cardiology*, Elsevier. 2019; p. 576-7.
8. Beerbaum P, Meyer H, Blum U. Ringkasan Penyakit Jantung Bawaan pada anak. Jakarta: UI Publishing 2019. p. 183-97.
9. Artman Michael, Lynn Mahony, David F. Teitel, *Neonatal Cardiology*, McGraw-Hill 2010; p 45-99.
10. Gildein HP, Kleinert S, Goh TH, et al. Pulmonary valve annulus grows after balloon dilatation of neonatal critical pulmonary valve stenosis. Am Heart J 2014;136:276-280
11. Rao PS. Percutaneous balloon valvuloplasty: state of the art. Catheter Cardiovasc Interv. 2007;69:747-63.
12. Klewer SE, Zamora R. Use of a cerebral angiographic catheter facilitates crossing the pulmonary valve in neonates with critical or severe pulmonary valve stenosis. Am J Cardiol 2017;80: 1245-47.
13. Holzer R, Qureshi S, Ghasemi A et al. Stenting of aortic coarctation: acute, intermediate, and long-term results of a prospective multi-institutional registry congenital cardiovascular interventional study consortium (CCISC). Catheter Cardiovasc Interv 2010; 4:553–63.
14. Bilkis AA, Alwi M, Hasri S, Haifa AL, Geetha K, LawHI. Critical Pulmonary stenosis in infants and neonates in era of interventional cardiology. Asian Cardiovasc Thorac Ann 1999; 7:40-2.
15. Caspi J, Coles JG, Benson LN, et al. Management of neonatal critical pulmonary stenosis in the balloon valvotomy era. Ann Thorac Surg 2012;49:273-278.
16. Ilker Kemal Yucel, Mustafa Orhan Bulut, Mehmet Kucuk, Sevket Balli and Ahmet Celebi, Intervention in Patients with Critical Pulmonary Stenosis in the Ductal Stenting Era, *Pediatric Cardiology* 2016; 10 :1037-45.
17. Kan JS, White RI, Mitchell SE, Gardner TJ. Percutaneous balloon valvulo-

- plasty: A new method for treating congenital pulmonary-valve stenosis. N Engl J Med 1982; 307:540-2.
18. Zipes. Braunwald's Heart Disease: A textbook of Cardiovascular Medicine. Seventh edition . London: Saunders; 2005. p. 232-74.
 19. Idrizi S, Milev I, Zafirovska P, Tosheski G, Zimbakov Z, Sokolov-VA, et al. Interventional treatment of pulmonary valve stenosis. OA Maced J Med Sci. 2015; 3:408-12.
 20. Latson L. Critical Pulmonary Stenosis. J of Intervent Cardiology 2001; 3: 345-50.